

Imaging Appearance of Ballistic Wounds Predicts Bullet Composition: Implications for MRI Safety

Arthur J. Fountain, MD¹, Amanda Corey, MD¹, John A. Malko, PhD^{1,2}, Davian Strozier, MBA, RT³, Jason W. Allen, MD, PhD^{1,4}

Multispecialty Articles • Original Research

Keywords

ballistic wounds, bullet, CT, MRI, safety

Submitted: May 5, 2020

Revision requested: May 21, 2020

Revision received: May 29, 2020

Accepted: Jun 1, 2020

First Published Online: Dec 23, 2020

The authors declare that they have no disclosures relevant to the subject matter of this article.

OBJECTIVE. The purpose of this article was to determine whether the radiographic and CT appearance of ballistic projectiles predicts their composition and to characterize the translational, rotational, and temperature effects of a 1.5-T MRI magnetic field on representative bullets.

MATERIALS AND METHODS. Commercially available handgun and shotgun ammunition representing projectiles commonly encountered in a clinical setting was fired into ballistic gelatin as a surrogate for human tissue, and radiographs and CT images of these gelatin blocks were obtained. MR images of unfired bullets suspended in gelatin blocks were also obtained using T1- and T2-weighted sequences. Magnetic attractive force, rotational torque, and heating effects of unfired bullets were assessed at 1.5 T.

RESULTS. Fired bullets were separated into ferromagnetic and nonferromagnetic groups based on the presence of a debris trail and deformation of the primary projectile in the gelatin blocks. Whereas ferromagnetic bullets showed mild torque forces and marked imaging artifacts at 1.5 T, nonferromagnetic bullets did not have these effects. Heating above the Food and Drug Administration limit of 2°C was not observed in any of the projectiles tested.

CONCLUSION. Patients with ballistic embedded fragments are frequently denied MRI because the bullet composition cannot be determined without shell casings. We found that radiography and CT can be used to identify nonferromagnetic projectiles that are safe for MRI. We also present an algorithm for determining the triage of patients with retained bullets.

As firearm-related urban violence and worldwide military engagements increase, embedded ballistic fragments are often encountered in patients admitted to hospitals and emergency departments. Many of these patients require imaging studies for diagnosis, prognosis, or both. Although CT is widely available and used, streak artifact from dense bullet fragments often obscures details of the adjacent structures, potentially leading to misdiagnosis or nondiagnostic studies. Furthermore, MRI has become the preferred imaging modality in several clinical scenarios, such as the characterization of brain tumors, spinal cord injury, and joint disorders. However, the presence of ferromagnetic materials in the magnetic field during MRI poses well-known risks due to migration, torque, and heating effects [1–4]. In particular, embedded ferromagnetic objects may cause serious injury, especially if they are located in soft tissues adjacent to vascular or neural structures. Therefore, MRI of patients with retained ballistic objects is frequently avoided because evidence of safety and knowledge regarding ballistic materials are lacking.

Published information on MRI safety concerning ballistic fragments is general in nature and includes warnings against heating and movement of these fragments [5]. Dedini et al. [2] conducted a study of MRI characteristics of several representative projectiles and concluded that bullets composed of a lead core and a copper jacket do not produce any significant image distortion and appear safe with respect to translational and twisting motion when exposed to up to 7-T field strengths. They also concluded that any steel-containing bullet is potentially unsafe because of movement in the magnetic field and artifact from the bullet, which frequently yields nondiagnostic images. Additionally,

¹Department of Radiology and Imaging Sciences, Emory University, 1364 Clifton Rd NE, Ste BG20, Atlanta, GA 30322. Address correspondence to J. W. Allen (jwallen@emory.edu).

²Department of Physics, Emory University, Atlanta, GA.

³Department of Radiology and Imaging Services, Grady Memorial Hospital, Atlanta, GA.

⁴Department of Neurology, Emory University, Atlanta, GA.

the authors found that heating of retained bullets or bullet fragments was not an issue for any bullet composition [2].

Although the presence of lead-core and copper-jacket bullets and lead pellets from an air gun or shotgun during MRI appears to be relatively safe, quick identification of the bullet composition before imaging is not always possible. The firearm, bullet, or spent case is frequently not available for identification either in the acute setting or, more commonly, during imaging for an unrelated health issue at a later date. A medical provider's knowledge about firearms and the radiographic appearance of ammunition is often limited unless the individual is a ballistics expert, forensic pathologist, or firearm enthusiast [6, 7]. Similarly, although two prior studies used dual-energy CT to identify the metallic composition of bullets [8, 9], the modality is not universally available, and expertise is required for image interpretation.

The most common weapon used in urban gun violence is the handgun, primarily the semiautomatic pistol. This type of weapon puts constraints on bullet construction, velocities, and penetration power. Shotgun and rifle injuries are encountered less often in the urban setting, and similar to handguns, the weapon characteristics require a specific class of ammunition. In contrast to urban areas, very rural and remote areas have a higher incidence of injuries resulting from long guns compared with handguns [10, 11].

The purpose of this study was to determine whether the radiographic and CT appearance of ballistic projectiles predicts their composition and to characterize the translational, rotational, and temperature effects of a 1.5-T MRI magnetic field on representative bullets. The primary objective was to test whether projectile composition can be determined by the appearance of the retained projectile and its debris track on CT images or radiographs. If the ballistic projectile composition can be determined, the risk associated with the patient undergoing MRI can be stratified into situations that pose little risk versus those that require more caution, potentially allowing more patients to undergo MRI. The secondary objective was to verify the translational, rotational, and temperature effects reported in the limited number of previous studies [2, 6, 7].

Materials and Methods

Ammunition Tested

All of the ammunition we tested is commercially available and known to be used in gun-related crimes [10, 11]. The bullets tested reflect the ammunition types used in the majority of the firearms traced and manufactured in the United States [12]. Bullets assessed with ballistic testing included solid lead (lead and antimony alloy), lead core with a full copper-alloy jacket, and alloy-jacket hollow points with or without a polymer plug in the tip. Jacketed bullets may have exposed lead at the tip (soft point), a hollowed tip (jacket hollow point [JHP]), or metal covering the point and sides (full metal jacket [FMJ]). Two types of rifle ammunition containing ferrous material were evaluated in the MRI magnet only and did not undergo ballistic testing: an M855 5.56-mm penetrator with a steel-core insert (Lake City Arsenal) and a very common .223 bimetal recreational round with a lead core with a mild steel jacket (Silver Bear).

The handgun types fired in our study are typical of those described in crime reports. Semiautomatic pistols that fire jacketed

ammunition and two revolvers with different calibers that fire both solid lead and jacketed cartridges were used. Table 1 lists the cartridges, bullet types, and firearms investigated in this study.

Gelatin Blocks

We used ballistic gelatin blocks (10% Ballistic Gelatin FBI Block, Clear Ballistics) made of traditional ordnance 240A ballistic gelatin, which approximates the mixed densities of living tissue for ballistic testing [13]. The gelatin blocks, which were calibrated to the specifications required for Federal Bureau of Investigation ordnance testing, measured 6 × 6 × 16 inches (15 × 15 × 41 cm) with a specific gravity of 0.91 and overall weight of 17.2 lb (7.8 kg). Blocks were cut into 8-inch (20-cm) lengths for the shotgun pellet test because limited penetration was expected.

MRI of bullets required two 1-quart (946-mL) plastic tubs of gelatin with the bullets embedded. The tubs were prepared by dissolving a 4× concentration of unflavored gelatin (Unflavored Gelatin, Kroger) in heated water and then pouring the gelatin into the two tubs. The gelatin was poured in three separate layers, allowing each layer to cool before pouring in the next layer. This procedure allowed us to position bullets between the second and third layers.

Live Fire on Ballistic Gel Blocks

Handguns with common calibers were used to fire 12 bullets composed of solid lead alloy, lead core with a copper-alloy jacket and a hollow point (JHP), or full copper-alloy jacket with a solid point (FMJ) into three different 6 × 6 × 16 inch (15 × 15 × 41 cm) blocks of ballistic gelatin located 7 yards (6 m) from the end of the handgun barrel. Guns were fired from a stable resting position with a safe and secure down range area. Table 1 lists the details of the projectiles fired into the blocks. A single cartridge (.45 automatic Colt pistol [ACP] FMJ, Federal Ammunition) was also fired through a deer cadaver skull located immediately in front of the ballistic gelatin block to simulate bone impact. The shotgun test was performed with the gelatin blocks located 10 yards (9 m) from the shotgun. A full choke was used for the lead shot, and a modified choke was used for the steel shot.

Imaging of Ballistic Gelatin Blocks After Live Fire

Conventional radiographs of each block were obtained in two planes (anteroposterior and lateral projections). CT images of blocks were acquired with a 64-MDCT scanner (VCT 64, GE Healthcare) at 0.625-mm slices and reformatted using the IntelliSpace CT Viewer (Philips Healthcare). All MRI examinations were performed on an Espree 1.5-T scanner (Siemens Healthineers).

MRI of Unfired Bullets

Because of distortion caused by the magnetic field, MRI is extremely sensitive to the presence of ferromagnetic material, so the presence of even a small amount of such material can distort the MR image over a wide volume. Therefore, MR images of selected unfired bullets were obtained using prepared gelatin tubs. Six nonferromagnetic bullets (#7 lead shot [Winchester], .45 Long Colt [Winchester], 5.56-mm Federal [Federal Ammunition], 5-mm pellet [Sheridan], .45 ACP Federal [Federal Ammunition], and .45 ACP Corbon [Corbon]) were positioned in tub A. Tub B contained only a single ferromagnetic .223 bullet (Silver Bear).

TABLE 1: Details of Ammunition Imaged After Being Suspended in Gelatin or Fired Into Ballistic Gelatin Blocks

Block No., Cartridge	Manufacturer	Bullet Type	Velocity ^a (f/s)	Bullet Weight (g)	Magnet Attraction ^b (N)	Torque ^b (N · m)	Ferromagnetic	MRI Performed (Tub)
Not fired ^c								
.223 bullet	Silver Bear	BiM	2800 (853)	4.1	2.2 ± 0.3	0.06 ± 0.01	Yes	Yes (B)
5.56-mm M855	Military Surplus	PN	2700 (823)	4.1	1.1 ± 0.3	< 0.02 ± 0.01	Yes	No
0.117 in, 4.5-mm BB	Daisy	Steel ball	400 (122)	0.4	Yes	NT	Yes	No
.45 Long Colt	Winchester	Pb RN	850 (259)	16.3	No	NT	No	Yes (A)
5.56 mm	Federal Ammunition	FMJ	2800 (853)	4.9	No	NT	No	Yes (A)
5-mm pellet	Sheridan	Pb RN ^d	400 (122)	1.0	No	NT	No	Yes (A)
Block #1								
.45 ACP	Federal Ammunition	FMJ	890 (271)	14.9	No	NT	No	Yes (A)
9-mm Parabellum	Winchester	FMJ	1180 (36)	7.8	No	NT	No	No
.357 Magnum	Winchester	FMJ	1130 (344)	10.2	No	NT	No	No
Block #2								
.45 ACP	Corbon	JHP	1150 (351)	12.9	No	NT	No	Yes (A)
9-mm Parabellum	Corbon	JHP	1350 (411)	7.8	No	NT	No	No
.357 Magnum	Hornady	JHP	1250 (381)	10.2	No	NT	No	No
Block #3								
.22 Long rifle	Federal Ammunition	Pb RN	1240 (378)	2.6	No	NT	No	No
.38 Special	Remington	Pb HP	850 (259)	10.2	No	NT	No	No
.38 Special	Remington	Pb RN	850 (259)	10.2	No	NT	No	No
.32 Smith and Wesson Long	Remington	Pb RN	755 (230)	5.8	No	NT	No	No
Block #4								
#7 Steel shot	Winchester	Steel ball	1145 (349)	< 0.1	Yes	NT	Yes	No
#7 Lead shot	Winchester	Lead ball	1200	< 0.01	No	NT	No	Yes (A)

Note—BiM = bimetal with steel jacket and copper plating, PN = lead core with steel tip and copper jacket, NT = not tested, Pb = solid lead with 5% antimony, RN = round nose, FMJ = full metal copper jacket closed at base, ACP = automatic Colt pistol, JHP = copper-alloy jacket with hollow point lead core, HP = hollow point.

^aAs listed by manufacturer. Numbers in parentheses are velocity in meters per second.

^bMean ± SD for six separate measurements.

^cBullets were not fired into a ballistic gelatin block.

^dAir gun.

(Table 1). The selected bullets represent common components and material combinations of ballistic projectiles.

Tub A was imaged with two gradient-recalled echo sequences (TR/TE, 500/10 and 700/30) and two spin-echo (SE) sequences (TR/TE, 400/9 and 5000/92). Tub B was imaged with two SE sequences (TR/TE, 7/2.5 [scout] and 480/10).

Heating Effects

During MRI, heating occurs when currents are induced by radiofrequency pulses and switching gradients in conducting materials. These currents then dissipate via resistive heating in the conducting material. The presence of a bullet or bullet fragment adds another conductor that may generate currents, causing resistive heating and temperature increase. We measured bullet

temperature during MRI using an MRI-compatible temperature sensor (FlexTEMP System Sensor, Invivo), which has a resolution of 0.1°C and an accuracy of 0.5°C. The selected bullets represented the two major categories of projectiles: ferromagnetic (5.56-mm Federal) and nonferromagnetic (.45 ACP Corbon). The sensor was taped directly to each bullet, which was then taped to the outside of a spherical fluid-filled MRI phantom. Touching the bullet with a bare finger would increase the detected temperature by 2°C within 10 seconds, indicating the sensitivity of the setup. During MRI of the bullet and phantom, bullet temperatures were monitored for 22 minutes. We used a TE turbo SE sequence (TR/TE, 4910/100; turbo factor, 16; number of signals acquired, 8; duration, 7 min) and a T2-weighted STIR sequence (TR/TE, 5640/28; turbo factor, 8; number of signals acquired, 6; duration,

15 min). Room temperature before and after the scans was recorded using a mercury thermometer with a resolution of 0.1°C.

Attractive Force Measurements

All bullets listed in Table 1 were assessed for ferromagnetism using neodymium magnets. The tested object was separated from the magnet by the thickness of a notecard. The card was removed, and the object was determined to be ferromagnetic if it showed any movement or could not be separated from the magnet. For the shotgun pellets, the magnet was placed in a collection of approximately 32 g of pellets, and the result was recorded.

The attractive force for two representative bullets, .223 bimetal and 5.56-mm M855 lead core with steel tip and copper jacket, was measured using a handheld spring scale (Table 1). One end of a string was taped to the bullet, and the other end of the string was attached to the spring scale, which was located outside of the 5-gauss line. The bullet was then pulled toward the magnet, and the maximum force detected by the spring was recorded. The mean of six separate force measurements is given in Table 1. This technique allows direct force measurement, whereas previously published techniques required calculation based on angle of deviation from vertical using a protractor and string [2].

Torque Measurements

A nonspherical ferromagnetic object that is misaligned with the long axis of a scanner's magnetic field will experience torque, which will attempt to twist the object into alignment. To measure the maximum possible torque, we constructed a plastic jig consisting of a wheel with a 4.1-cm radius that was free to rotate on a low-friction axis. The same bullets used for attractive force measurements, .223 bimetal and 5.56-mm M855, were used for torque measurements (Table 1). Each bullet was fixed in turn to the wheel at the pivot point. The jig was then positioned in the center of the scanner magnet, and the long axis of the bullet was

allowed to align with the scanner's long axis. A string that had been wrapped around the circumference of the wheel ran outside the magnet and was attached to a handheld spring scale located outside the 5-gauss line. The scale was then pulled so that the bullet's alignment was forced to rotate past the direction perpendicular to the long axis of the scanner. The maximum force needed to accomplish this was recorded as measured on the spring scale. This force was then multiplied by the distance of the string from the wheel's pivot point to calculate torque. The mean of six separate torque measurements is given in Table 1.

Results

Radiographic and CT Appearance of Fired Bullets

Figures 1 and 2 show selected radiographs and CT images of the three live-fire ballistic gelatin blocks. Of the FMJ bullets fired into block #1, only the .45 ACP bullet that traversed the deer cadaver skull left a debris track containing bone that was visible on both the CT maximum-intensity-projection image and the anteroposterior radiograph (Fig. 1). The .45 ACP FMJ bullet that did not traverse the skull left no trail and landed in the down range area after exiting the gelatin block. Each trail in block #1 contained a small amount of air. However, cavitation was not a significant issue because of velocities and lack of expansion. All FMJ bullets completely penetrated the gelatin block with no metallic debris trail visible on CT images or radiographs. All of the FMJ bullets were recovered, and none showed any appreciable deformity.

All of the copper-jacket with lead-core JHP bullets fired into block #2 deformed and fragmented on impact, leaving debris trails of tightly clustered metal particles along the bullet track (Fig. 1). In contrast to the FMJ bullets, the JHP bullets had limited penetration and did not pass completely through the block. The .357 Magnum (8.3-inch [21.1-cm] penetration, Hornady), 9-mm Parabellum (10.0-inch [25.4-cm] penetration, Corbon), and the




Fig. 1—Maximum-intensity-projection (MIP) CT and radiography of handgun ammunition fired into ballistic gelatin blocks. Paper clips seen in radiographs were used to ensure correct orientation during imaging.
A, MIP CT image (top) and radiograph (bottom) show trails of three full metal jacket bullets fired into block #1: .45 automatic Colt pistol (ACP; Federal Ammunition), 9-mm Parabellum (Winchester), and .357 Magnum (Winchester). Only .45 ACP bullet fired through deer cadaver skull left visible debris trail that consisted of osseous fragments (arrows). All other bullets, including .45 ACP not fired through skull, passed completely through block without detectable CT or radiographic trail.
B, MIP CT image (top) and radiograph (bottom) show trails of three copper-jacket with lead core hollow point bullets fired into block #2: 9-mm Parabellum (Corbon) (black arrows), .45 ACP (Corbon) (white arrows), and .357 Magnum (Hornady) (arrowheads). All of these bullets deformed on impact and left metallic debris trail clustered along bullet path.
C, MIP CT image (top) and radiograph (bottom) show trails of four solid lead bullets fired into block #3: .22 long rifle round nose (Federal Ammunition) (white arrowheads), .38 Special hollow point (Remington) (arrows), .38 Special round nose (Remington), and .32 Smith and Wesson Long (Remington) (black arrowheads). Both .38 Special bullets passed through gelatin, and .38 Special hollow point left faint metallic debris trail on MIP CT image. Remaining bullets stayed in gelatin block with appreciable deformity.

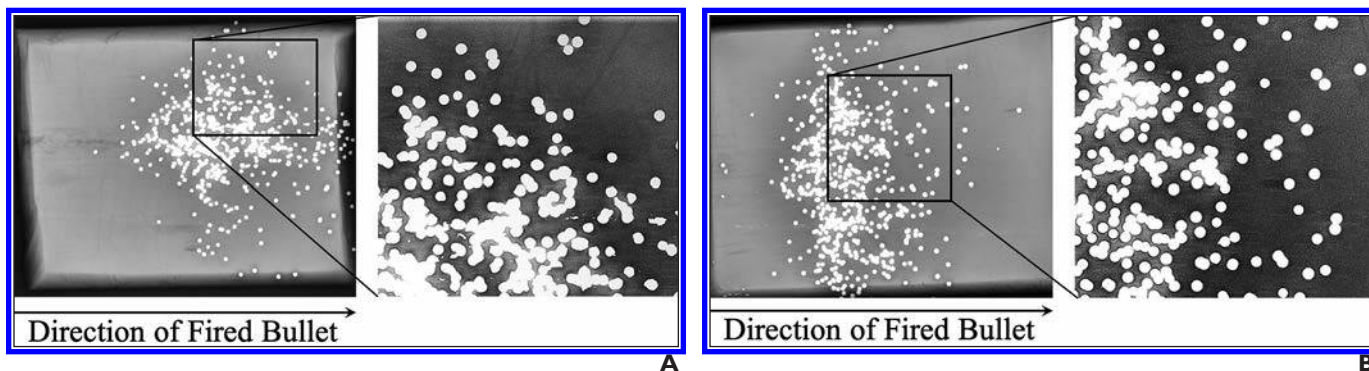


Fig. 2—Radiography of shotgun ammunition fired into ballistic gelatin blocks.

A, Radiograph (left) shows deformation of lead shot discharged into block #4. Deformation is better appreciated in magnified image (right) of area of radiograph bounded by black box.

B, Radiograph (left) shows steel shot fired into block #5. Unlike lead shot, no appreciable deformation is seen in main image or magnified image (right) of area of radiograph bounded by black box.

.45 ACP (10.0-inch [25.4-cm] penetration) bullets expanded on impact and left heavy debris trails (Fig. 1).

The solid lead bullets fired into block #3 did not deform on impact (Fig. 1). The .32 Smith and Wesson Long (Remington) and the .22 long rifle (Federal Ammunition) round nose bullets penetrated 10.0 and 12.2 inches (25.4 and 31.0 cm), respectively. The two bullets from the more powerful .38 Special cartridges (Remington) with lead round nose and lead hollow point passed through the block. Only the .38 Special hollow point bullet left a metallic debris trail, which was minimal. Separate blocks were used for lead shotgun shot imaging (Fig. 2). Deformation of the lead shot is visible on the radiograph. In contrast, the steel shot maintained a spherical contour. The midpoint of the lead shot cluster penetrated 5.0 inches (12.7 cm), whereas the midpoint of the steel shot cluster penetrated 3.5 inches (8.9 cm).

MRI Appearance of Bullets

Figure 3 shows the T1- and T2-weighted MR images of the gelatin tub containing the unfired, nonferromagnetic bullets. In all images, the bullets are seen as signal voids, which are larger than the bullet sizes because of susceptibility artifacts. As expected, the signal voids are larger on the gradient-recalled echo images compared with the SE and scout images. In addition, blooming effects were more pronounced on images with increased TE. Scout and T1-weighted SE images of the gelatin block containing a single ferromagnetic bullet show severe signal voids and geometric distortions (Fig. 4).

Temperature Measurements

A temperature increase of 0.4°C occurred in the .45 ACP Carbon nonferromagnetic bullet, with a corresponding room temperature increase of 0.3°C. Similarly, a temperature increase of 0.2°C occurred in the 5.56-mm Federal ferromagnetic bullet, with a corresponding room temperature increase of 0.2°C. Thus, a bullet temperature increase of no more than 0.1°C can be attributed to MRI effects.

Forces and Torque

The mean of six separate force and torque measurements was calculated for each bullet tested. The mean maximum force and torque were measured for the .223 bimetal bullet with a copper

coated steel jacket and the 5.56-mm M855 bullet with the steel insert. The values for the 5.56-mm M855 bullet were half those of the .223 bimetal bullet (Table 1). Force and torque were measured before the bullets were put into the gelatin blocks and were not strong enough to disturb the orientation of any of the bullets while in the gelatin blocks. Four projectiles exhibited detectable attraction to the neodymium magnets, indicating ferromagnetic properties. None of the ammunition that fragmented on impact with the gelatin blocks showed any attraction.

Discussion

This study had two objectives: to test the hypothesis that ballistic projectile type can be determined by the radiographic appearance of a debris track and retained projectile, and to verify translational, rotational, and heating effects of commonly encountered bullets. Radiologists should be able to help determine the composition of ballistic material to predict the effect of the magnetic field on the retained shrapnel and potential image degradation. The bullets we tested that left a debris track or appeared deformed on radiographs or CT images are not ferromagnetic, do not significantly heat up or produce detectable force or torque during MRI, and do not produce much artifact on T1- or T2-weighted MR images.

We used ballistic gelatin as a surrogate to investigate the behavior of the ammunition within human tissue and to determine key imaging findings that predict projectile composition. The density of this medium can be varied to allow different test conditions. Though an exact substitute for something as complex as living tissue (e.g., skin, fat, muscle, fascia, blood, organs) is not possible, the overall density can be approximated with gelatin [2, 14–16]. We focused on handgun (revolver and semiautomatic pistol) ammunition, because wounds from handguns are the most likely to be encountered in the nonmilitary medical setting [10, 11].

The semiautomatic pistol and the revolver are the two most common types of handguns. The pistol operates in a semiautomatic fashion, such that the fired cartridge energy expels the spent round, cocks the firing mechanism, and reloads a fresh cartridge in the chamber of the barrel. The violent transfer of the cartridge through the lips of the magazine onto the metal loading ramp and finally into the throat of the barrel chamber requires the bullet to be sturdy enough to withstand the extensive metal-to-metal




Fig. 3—MRI of nonferromagnetic ballistics suspended in gelatin. **A–E**, Scout (**A**), T1-weighted spin-echo (SE) (**B**), T2-weighted SE (**C**), T2-weighted gradient-recalled echo (GRE) (TR/TE, 500/10; **D**), and T2-weighted GRE (TR/TE, 700/30; **E**) MR images show jacket hollow point .45 automatic Colt pistol bullet (Corbon) (1), solid lead .45 Long Colt bullet (Winchester) (2), full metal jacket (FMJ) automatic Colt pistol bullet (Winchester) (3), 5.56-mm FMJ bullet (Federal Ammunition) (4), #7 lead shotgun pellet (Winchester) (5), and 5-mm lead air gun pellet (Sheridan) (6). On all sequences, metallic artifact is minimal. Although metallic artifact increases or blooms with increased TR/TE in GRE images (**D** and **E**), amount of surrounding distortion is still minimal.





Fig. 4—MRI of single ferromagnetic .223 bimetal bullet fired into ballistic gelatin block. **A** and **B**, Scout (**A**) and T1-weighted spin-echo (**B**) MR images show severe metallic artifact on both sequences.



contact. A durable metal cover over a lead bullet is required to resist deformity. This metal cover is referred to as a jacket. The jacket can be made of any malleable material, most commonly copper, copper alloy, brass, nickel, zinc, and mild (low-carbon) steel. A jacketed bullet may have lead exposed at the tip (soft point), a hollowed tip (JHP), or the point and sides covered in metal (FMJ). JHP and FMJ bullets are very durable and very difficult to deform, as shown in our live-fire test.

The revolver holds the cartridges in a cylinder. In a single-action revolver, the hammer is pulled back, a fresh cartridge is rotated in line with the barrel, and the firing mechanism is cocked and fired with a separate pull of the trigger. Alternately, in a double-action revolver, the trigger pull rotates the cylinder into place, cocks the firing mechanism, and releases the hammer to fire the gun. The bullet construction can be soft lead or jacketed.

Gunshot wounds from most rifles and close-range shotgun encounters are uncommon in the emergency department setting because injuries sustained produce severe tissue destruction and are often lethal [15, 17]. Usually, a patient who has survived a shotgun injury and presents for MRI will have a sprinkle of small pellets (shot size of 2.30–2.79 mm) in the subcutaneous tissues, because the small shots have limited penetration, as confirmed in our live-fire test (Fig. 2). These smaller pellets are most commonly made of lead with a small amount of antimony for hardness. Steel pellets are far less common than lead pellets and are primarily used to hunt migratory game birds [1]. For comparison, buckshot sizes range from 6.1 mm for #4 shots to 9.14 mm for 000 shots and are composed of lead [18]. The larger shot sizes were not test fired in the current study.

MRI has become the standard of care for many types of medical conditions, and uniformly denying MRI to patients with a history of a gunshot wound may impact care. The major difficulty in deciding whether to image a patient with a gunshot wound is the accurate identification of the bullet composition without the case or retrieved bullet, because neither is likely to be available in the clinical setting, particularly for a remote injury [2, 5]. The majority of relevant published articles have discussed the radiographic appearance of various types of discharged rifle bullets, with an emphasis on military or hunting ammunition [15, 17]. To our knowledge, studies on the appearance of the ballistic bullet trail and the correlation with behavior of projectiles in the MRI magnetic field have not been published.

Bullets that leave a metallic debris trail on entry are designed to disperse energy into the target. In handgun ammunition, the bullet deforms into a mushroom shape, which also limits penetration [19, 20]. As opposed to high-velocity rifle projectiles (≥ 1600 feet/s [488 m/s]), which generally pass through the victim, handgun bullets travel at 800–1300 feet/s (244–396 m/s), and the associated fragments cluster along the wound trail as opposed to extending into the surrounding tissue [13, 15, 17]. For example, JHP bullets are made of a nonferromagnetic copper or copper-alloy jacket with a lead core and a hollow tip to aid expansion. Some bullets have nickel jackets, but these are rare in the United States, and we have not been able to locate a source. In our study, the bullets leaving a debris trail or showing deformation detectable on radiography or CT included the .45 ACP JHP, 9-mm Parabellum JHP, .357 Magnum JHP, .38 Special HP, and lead shot. In addition, the .45 ACP FMJ that traversed a deer cadaver skull left a debris trail, though the trail was made of osseous fragments. Our study advances the literature in that bullet penetration was measured and debris trails and ballistic projectile tracks were systematically assessed with radiography and CT, in contrast with earlier studies. The early appearance of fragmentation on entry with a narrow metallic debris trail and limited penetration implies a nonferromagnetic composition, so MRI would pose little or no risk to patients injured with these bullets. Additionally, in our experience, nonferromagnetic ballistic fragments produce minimal or no artifact on standard MR images (Fig. 5).

Bullets that do not leave a metallic debris trail are made of either solid lead or FMJ. Though both of these may deform on impact if traveling at velocities more than 2000 feet/s (610 m/s), this speed requires a rifle, and injuries related to rifles are rare in most clinical settings [7, 10, 11]. At handgun velocities of 800–1300 feet/s (244–396 m/s), FMJ bullets will show little deformation.

Because radiographs and CT images only show bullet profiles, they cannot be used to determine whether nondeformed bullets without a debris trail are solid or jacketed or whether the bullet core jacket composition is steel, nickel, or copper. In this situation, the need for an MRI examination must be seriously considered along with the age of the wound and position of the ballistic remnants. Radiologists must consider these bullets to be ferromagnetic until proved otherwise and use appropriate MRI precautions.

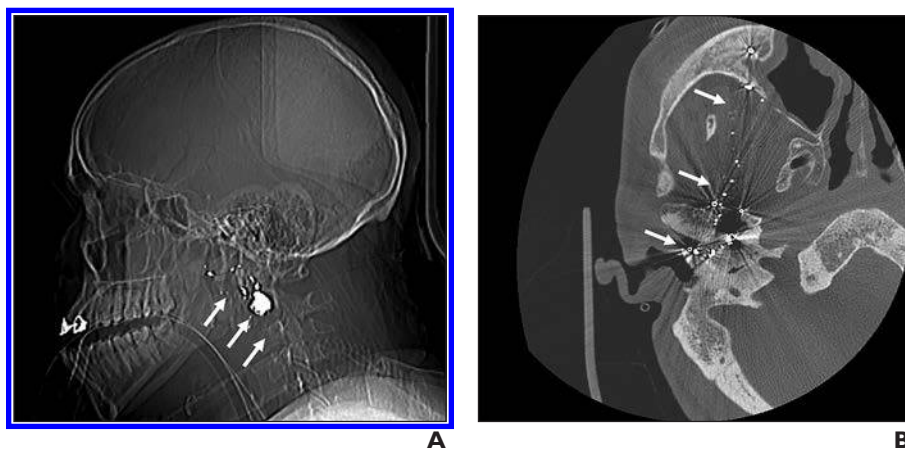


Fig. 5—26-year-old woman with facial injury from nonferromagnetic bullet.

A and B, Scout (**A**) and axial (**B**) CT images show multiple metallic fragments along bullet track (arrows). Deformed bullet is evident on both images.

(Fig. 5 continues on next page)

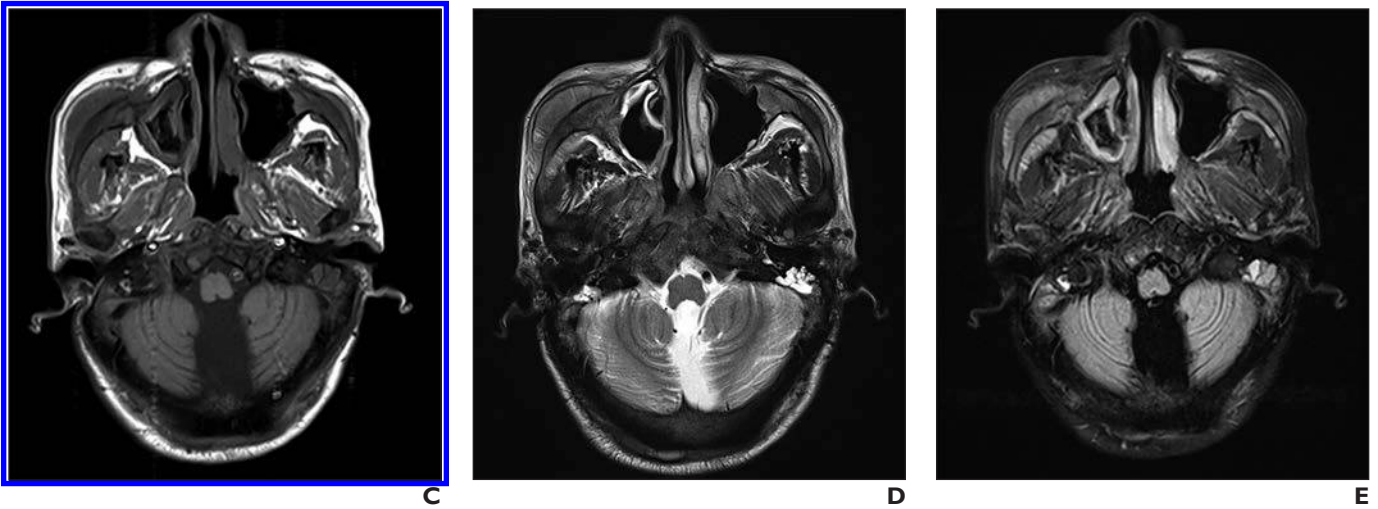


Fig. 5 (continued)—26-year-old woman with facial injury from nonferromagnetic bullet.

C–E, Subsequent axial T1-weighted (**C**), T2-weighted spin-echo (**D**), and T2-weighted FLAIR (**E**) standard brain MR images show minimal or no appreciable metallic artifact, compatible with nonferromagnetic bullet.

For objects with weak ferromagnetism that are embedded in soft tissue or a vessel, a conservative estimate of at least 6–8 weeks after object implantation has been suggested as a safe time interval before performing MRI at 1.5 T [21]. However, the same material may be imaged immediately after implantation if imbedded in bone [1, 5]. To our knowledge, recommendations regarding a safe waiting period before imaging such objects in the spinal canal, orbit, or brain have not been published. Even if imaging were possible in these regions, the artifact from a ferromagnetic bullet would likely obscure most diagnostic detail (Fig. 4).

We found that shotgun pellets exhibiting at least mild deformation on radiographs showed no susceptibility artifact on MRI and were made of lead. Though shotgun shells composed of a tungsten and epoxy combination or bismuth are also available for purchase, they are very expensive and almost exclusively used for migratory bird hunting [1]. Additionally, bullets of these compositions appear primarily fractured as opposed to deformed on radiographs of animal carcasses [18]. Similarly, as confirmed in our study, steel shot does not deform, even on impact with bone [15, 17, 18, 22]. Therefore, the presence of deformed shotgun pellets would suggest they are composed of lead. Lead shots are not ferromagnetic and pose little or no risk for MRI.

In addition to investigating the radiographic appearance of fired ballistic projectiles, we also characterized the behavior of representative unfired cartridges when placed in a 1.5-T magnetic field. Our results are in accordance with prior studies that assessed heating, torque, attractive forces, and imaging degradation effects of a retained ballistic object.

In 1990, Teitelbaum et al. [7] performed a detailed assessment of the safety and image quality issues associated with MRI in patients with retained metallic ballistic fragments. The study addressed the extensive blooming artifact of ferromagnetic material. This problem primarily occurred with FMJ bullets with a steel-jacket or steel-core construction, and this composition was most commonly noted in pistol ammunition manufactured outside of the United States or in select military ammunition regardless of country of origin. These classes of ferromagnetic cartridges were also associated

with deflections when placed in the magnetic field. The study did not present any data on potential heating of the fragments. Additionally, the authors did not find a satisfactory method for using radiographs to identify the type of bullet and indicated that the cartridge case was necessary for identification.

In 2000, Hess et al. [6] surveyed 56 different rifle and handgun projectiles, including steel and lead shotgun pellets, for susceptibility artifact and movement on 0.2-T and 1.5-T MR images. They did not identify any movement or significant artifact for nonferromagnetic projectiles. Heating was not considered an issue because of the small size of the bullets, though no measurements were obtained. These authors also stated that pretesting a projectile was the only way to determine MRI safety, similar to Similar to Teitelbaum et al. [7].

To our knowledge, in 2013, Dedini et al. [2] published the first work addressing common bullet configuration reactions in MRI field strengths up to 7 T. They included detailed torque, attraction, and temperature data and assessed image quality of ferromagnetic fragments. Similar to our study, Dedini et al. found minimal temperature changes of bullets in the MRI scanner, with a maximum increase in temperature of 1.7°C at 3 T for a variety of bullets, including ferromagnetic ballistics. Torque and attraction within the various field strengths were only determined for ferromagnetic bullets, and these bullets also produced severe image distortion. Our results from temperature assessments at 1.5 T confirm these findings. Attraction and torque are only an issue for ferromagnetic projectiles. Heating is not an issue regardless of the bullet construction. The Food and Drug Administration limit on local heat generation during MRI is 2°C [1], and no projectile generated more heat than this in our study or in the study by Dedini et al.

Although our study focused on handgun ammunition, single subcutaneous BB bullets, which are 4.57-mm spheres, are not uncommonly encountered in patients with projectile wounds who present for imaging. These projectiles typically do not deform because of the mild copper-plated steel construction. Given the low penetrating power of BBs, they are generally found within subcutaneous tissue or muscle. Because heating is not an issue

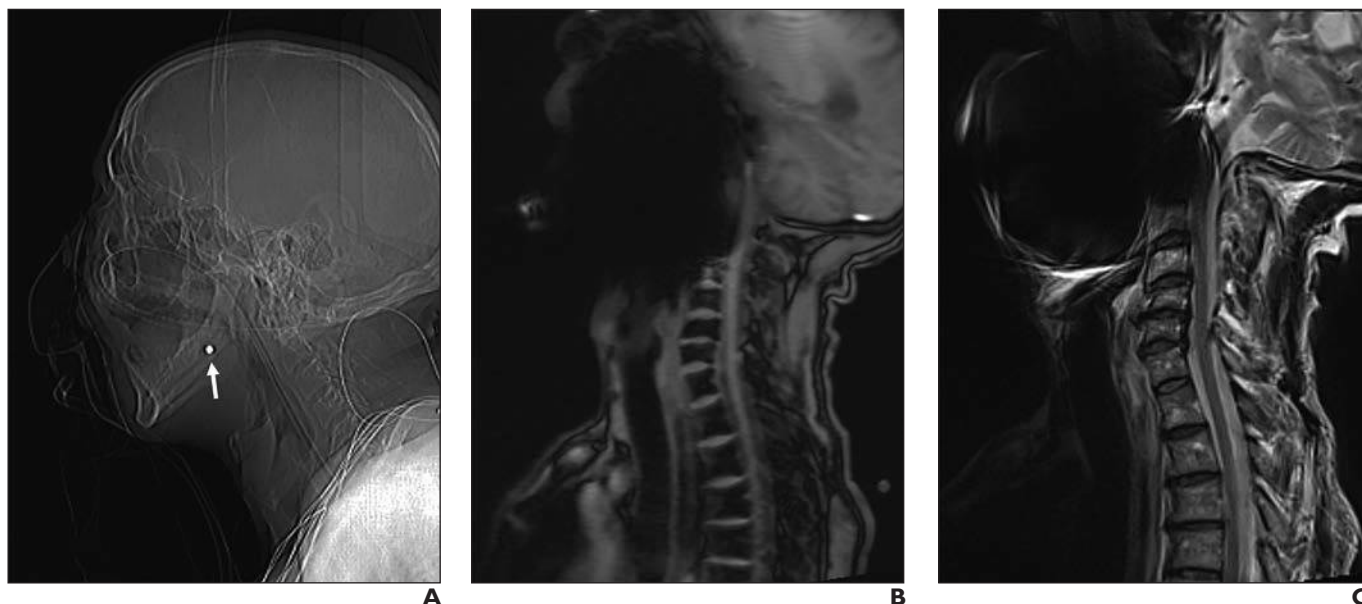


Fig. 6—63-year-old woman with facial injury from BB bullet. **A**, Scout CT image shows BB (arrow) embedded in facial soft tissues. **B** and **C**, Sagittal scout (**B**) and T2-weighted (**C**) MR images show metallic artifact from BB extending throughout face and upper cervical spine.

and spheres do not experience torque, the major issue with an embedded BB is the distortion of the image (Fig. 6).

On the basis of our findings and previously published reports, we propose the following algorithm for the triage of patients with retained ballistic projectiles who need an MRI examination (Fig. 7). Radiologists should review radiographs or CT images (or both) of the region containing the bullet to determine the presence of a debris track, deformation of the primary projectile, or both. The

presence of either indicates the bullet is either a JHP or lead shot and is therefore nonferromagnetic and safe for MRI, regardless of when the injury occurred of the injury. If neither is present but the retained projectile is round and matches the characteristics of a BB, MRI may be attempted safely, although artifact may decrease the diagnostic utility depending on the distance between the bullet and the artifact. If no debris track is evident and the bullet is not deformed, the composition of the bullet cannot

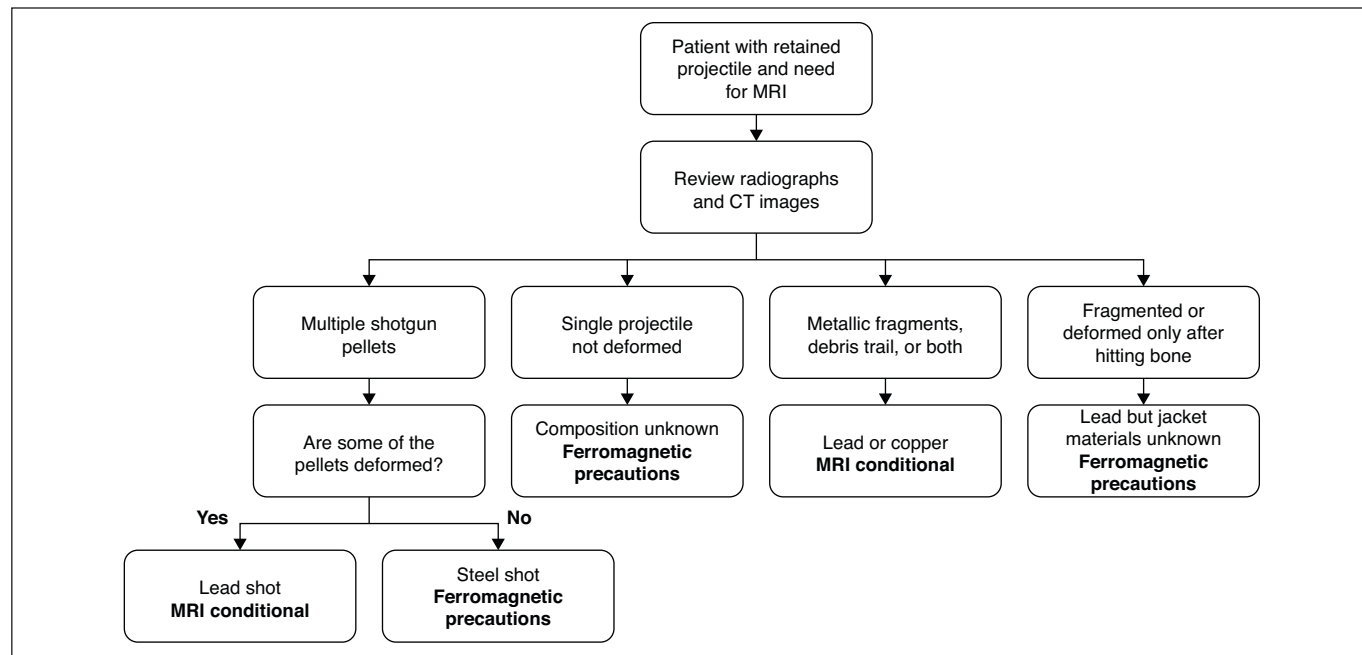


Fig. 7—Proposed algorithm for triage of patients with embedded ballistic projectiles who need to undergo MRI examination. Recommendations for MRI are in bold. MRI conditional indicates imaging is safe at 1.5 T. Ferromagnetic precautions indicate risk-benefit analysis is required before proceeding with MRI.

be determined without the casing, and torque induced by the magnet may move the bullet. Similarly, shotgun pellets that are not deformed should be considered ferromagnetic steel shots. These ferromagnetic ballistic projectiles will produce marked artifact on MR images, and the risk-to-benefit ratio should be considered before MRI is performed. In addition, all other MRI safety guidelines should be followed when scanning patients with ballistic projectile injury, regardless of the object's composition [4].

Conclusion

MRI has generally been considered as unsafe for patients with retained bullet fragments or shotgun pellets largely because of the uncertainty of the projectile composition in the absence of the casing. We found that ballistic projectiles can be separated into ferromagnetic and nonferromagnetic bullets on the basis of their appearance on radiography or CT, allowing patients with embedded nonferromagnetic bullets to safely undergo MRI. We have suggested a triage algorithm for patients with retained ballistic fragments. In particular, a projectile that leaves a metallic debris trail from entry to final position or has been appreciably deformed is of copper, copper-alloy, or lead composition with a partial jacketed configuration or represents lead shotgun shot and does not pose a significant risk for imaging at 1.5 T or less, regardless of when the injury occurred. Nonferromagnetic ballistic projectiles do not undergo movement or heating during MRI, and the imaging modality can be performed when medically necessary without undue risk and with limited artifact susceptibility on the resulting images, even when the projectile is in or near a vital structure.

Acknowledgment

We thank Siemens Healthcare for generously supplying the MRI temperature probe used in this study.

References

- Shellock FG, Crues JV. MR procedures: biologic effects, safety, and patient care. *Radiology* 2004; 232:635–652
- Dedini RD, Karacozoff AM, Shellock FG, Xu D, McClellan RT, Pekmezci M. MRI issues for ballistic objects: information obtained at 1.5-, 3- and 7-tesla. *Spine J* 2013; 13:815–822
- Alvis-Miranda HR, Rubiano Escobar AM, Agrawal A, et al. Craniocerebral gunshot injuries: a review of the current literature. *Bull Emerg Trauma* 2016; 4:65–74
- Greenberg TD, Hoff MN, Gilk TB, et al.; ACR Committee on MR Safety. ACR guidance document on MR safe practices: updates and critical information 2019. *J Magn Reson Imaging* 2020; 51:331–338
- Kanal E, Barkovich AJ, Bell C, et al.; Expert Panel on MR Safety. ACR guidance document on MR safe practices: 2013. *J Magn Reson Imaging* 2013; 37:501–530
- Hess U, Harms J, Schneider A, Schleef M, Ganter C, Hannig C. Assessment of gunshot bullet injuries with the use of magnetic resonance imaging. *J Trauma* 2000; 49:704–709
- Teitelbaum GP, Yee CA, Van Horn DD, Kim HS, Colletti PM. Metallic ballistic fragments: MR imaging safety and artifacts. *Radiology* 1990; 175:855–859
- Winklhofer S, Stolzmann P, Meier A, et al. Added value of dual-energy computed tomography versus single-energy computed tomography in assessing ferromagnetic properties of ballistic projectiles: implications for magnetic resonance imaging of gunshot victims. *Invest Radiol* 2014; 49:431–437
- Gascho D, Zoelch N, Richter H, Buehlmann A, Wyss P, Schaeferli S. Identification of bullets based on their metallic components and x-ray attenuation characteristics at different energy levels on CT. *AJR* 2019; 213:[web]W105–W113
- Planty M, Truman JL. *Firearm violence, 1993-2011*. Washington, DC: Bureau of Justice Statistics, 2013
- Brown EG. *Firearms used in the commission of crimes*. Sacramento, CA: California Department of Justice, 2009
- Bureau of Alcohol, Tobacco, Firearms and Explosives website. Annual firearms manufacturing and export report, 2018. www.atf.gov/file/142946/download. Accessed May 24, 2020
- Nicholas NC, Welsch JR. *Ballistic gelatin*. University Park, PA: Pennsylvania State University, 2004
- Juliano TF, Moy P, Forster AM, Weerasooriya T, VanLandingham MR. *Multi-scale mechanical characterization of biomimetic gels for army applications*. Adelphi, MD: U.S. Army Research Laboratory, 2006
- Santucci RA, Chang YJ. Ballistics for physicians: myths about wound ballistics and gunshot injuries. *J Urol* 2004; 171:1408–1414
- Ryckman RA, Powell DA, Lew A. Ballistic penetration of Perma-Gel. *AIP Conf Proc* 2012; 1426:143–148
- Bartlett CS. Clinical update: gunshot wound ballistics. *Clin Orthop Relat Res* 2003; 408:28–57
- Mann MJ, Espinoza EO, Ralston RM, Stroud RK, Scanlan MD, Strauss SJ. Shot pellets: an overview. *AFTE J* 1994; 26:223–241
- Hollerman JJ, Fackler ML, Coldwell DM, Ben-Menachem Y. Gunshot wounds. Part 1. Bullets, ballistics, and mechanisms of injury. *AJR* 1990; 155:685–690
- Hollerman JJ, Fackler ML, Coldwell DM, Ben-Menachem Y. Gunshot wounds. Part 2. Radiology. *AJR* 1990; 155:691–702
- Levine GN, Gomes AS, Arai AE, et al. Safety of magnetic resonance imaging in patients with cardiovascular devices: an American Heart Association scientific statement from the Committee on Diagnostic and Interventional Cardiac Catheterization, Council on Clinical Cardiology, and the Council on Cardiovascular Radiology and Intervention—endorsed by the American College of Cardiology Foundation, the North American Society for Cardiac Imaging, and the Society for Cardiovascular Magnetic Resonance. *Circulation* 2007; 116:2878–2891
- Dahlstrom DB, Powley KD, MacPherson D. *Lead shot penetration in 10% ordnance gelatin*. Ottawa, ON, Canada: Canadian Police Research Centre, 1995

This article has been cited by:

1. Noah Ditkofsky, Joel A. Gross, Justin P. Dodge. Ballistic Debris of Unknown Composition Should Be Considered MRI Conditional. *American Journal of Roentgenology*, ahead of printW1-W1. [[Citation](#)] [[Full Text](#)] [[PDF](#)] [[PDF Plus](#)]
2. Arthur J. Fountain, Amanda Corey, John A. Malko, Davian Strozier, Jason W. Allen. Reply to “Ballistic Debris of Unknown Composition Should Be Considered MRI Conditional”. *American Journal of Roentgenology*, ahead of printW1-W1. [[Citation](#)] [[Full Text](#)] [[PDF](#)] [[PDF Plus](#)]